



Sharp-Needle Intradermal Fat Grafting (SNIF)

Assaf A. Zeltzer, MD, FCCP; Patrick L. Tonnard, MD; and
Alexis M. Verpaele, MD

Aesthetic Surgery Journal
32(5) 554–561
© 2012 The American Society for
Aesthetic Plastic Surgery, Inc.
Reprints and permission:
[http://www.sagepub.com/
journalsPermissions.nav](http://www.sagepub.com/journalsPermissions.nav)
DOI: 10.1177/1090820X12445082
www.aestheticsurgeryjournal.com



Abstract

Background: Reversing the effects of facial aging is best accomplished with a combination of techniques. Minimizing the appearance of fine wrinkles is an essential part of treatment, which can involve resurfacing, intradermal filler injections, or a combination of the two. The quest for the ideal filler material is ongoing, but intradermal fat injections can serve as an inexpensive and safe alternative to classic intradermal fillers.

Objectives: The aim of this study was to evaluate the feasibility, validity, and safety of the sharp-needle intradermal fat grafting (SNIF) technique.

Methods: The records of 250 consecutive patients treated over a 3-year period with the authors' SNIF technique were reviewed to evaluate the SNIF technique and its results, including complications.

Results: Results were evaluated by clinical examination and patient photographs. Good improvement was achieved with SNIF, with results lasting more than 1 year, which exceeds the expected duration for resorbable dermal fillers (typically 3 to 6 months). No major complications occurred; the most common minor complications were bruising and swelling.

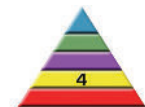Conclusions: SNIF is a safe and effective alternative to classic resorbable dermal fillers for patients who can accept the minor discomfort involved in extracting fat from the donor site. The harvesting and injection techniques should be performed with precision to achieve favorable results and avoid complications.

Level of Evidence: 4

Keywords

fat grafting, intradermal, filler, sharp needle

Accepted for publication January 18, 2012.



Aging of the skin is a multifactorial process that involves intrinsic and extrinsic factors. The primary intrinsic factor is a decrease in dermal thickness, owing to reductions in collagen, elastin, and hyaluronic acid.

The major extrinsic contributor is sun exposure; however, other environmental factors such as smoking and pollution also play an important role.¹ Mechanical elements, including gravity and repetitive facial movements, are also involved in the development of wrinkles.

Facial sagging, damage to the skin surface, and deflation of facial volume are conditions that contribute to the need for treatment. Modern facial rejuvenation requires that the practitioner address all these aspects. Sagging can be treated with facelift techniques. Deflation of facial volume can be treated with classic lipofilling techniques (volumetric buildup). Damaged skin can be treated with skin resurfacing techniques (lasers, peels, dermabrasion) and/or injection of intradermal fillers. These injections can be performed alone or in conjunction with surgical facial rejuvenation. Dermal filling has become an increasingly popular method to help reverse the effects of skin

aging in a minimally invasive manner, and it is often sought by relatively young patients (in their 30s and 40s). Classic dermal fillers are generally categorized as permanent or resorbable. Permanent fillers have a higher complication rate than their resorbable counterparts.² The temporary nature of resorbable fillers is an obvious disadvantage.

Dr Zeltzer is an attending plastic surgeon at the University Hospital, Brussels, Belgium. Dr Tonnard and Dr Verpaele are plastic surgeons in private practice in Gent, Belgium.

Corresponding Author:

Dr Patrick L. Tonnard, MD, Coupure rechts 164 c-d, 9000 Gent, Belgium. E-mail: info@coupurecentrum.be



Scan this code with your smartphone to see the operative video. Need help? Visit www.aestheticsurgeryjournal.com.

The quest to find the ideal dermal filler is ongoing. Based on our experience with fine-particle fat grafting for lipofilling and on published reports of the use of dermal fillers,³⁻⁶ we began performing fine particle, sharp-needle intradermal fat grafting (SNIF) injections in 2008 and have since performed this technique in 250 consecutively treated patients. This article describes our 3-year experience with this alternative technique of dermal filling.

METHODS

Study Design

We retrospectively reviewed the charts of 250 patients who underwent SNIF treatment with 1 of the 2 senior authors (PLT or AMV) between January 2008 and September 2011. Patient demographic data were collected, along with information about concurrent or adjunct procedures and complications.

The SNIF Procedure

Fat harvesting. Intradermal fat grafting can be performed in conjunction with other facial rejuvenation procedures, with the patient under general or local anesthesia. Fat is harvested at the time of facial infiltration, using an adrenaline-containing local anesthetic. The preferred donor site for fat harvesting is the infraumbilical area because of the ease of approach while the patient is supine. This area is marked preoperatively, with the patient standing. Other donor areas for consideration include the "love handles" and the internal side of the thigh or knee.

After skin preparation and draping, a modified Klein solution containing 800 mg of lidocaine and adrenaline (1/1 000 000) was infiltrated as for regular liposuction.⁷ We used a "wet" technique for infiltration (2:1 ratio of infiltrate to aspirate). A 2-mm stab incision was made along the skin-tension lines with a number 11 blade. Suction lipectomy was performed manually, with sterile syringes or with a suction device and a sterile canister. If the desired volume of fat was less than 10 mL, the fat was harvested with a cannula on a 10-mL Luer-Lok syringe. Volumes of more than 10 mL were harvested with a suction device and a sterile canister.

The suction cannula had a diameter of 2 or 3 mm, with multiple sharp 1-mm holes at its top segment (Figure 1; Tulip Medical Products, San Diego, CA). The limited diameter of the cannula holes is important for obtaining small particles to be injected through a 23-gauge needle. Thus, the SNIF technique is very different from classic lipofilling procedures. The sharp edges of the holes augment the harvesting yield of the suctioned fat, because the cannula works like a rasp in the donor area. A yield of 1 mL of fat graft per 5 mL of aspirate can be expected.

A sterile nylon cloth with 0.5-mm mesh size was mounted over a sterile canister, and the supernatant was poured over it (Figure 2). The fat was rinsed with normal



Figure 1. The harvesting cannula consists of a multiport sharp cannula, 2 mm in diameter, with holes of 1 mm in diameter (Tulip Medical Products, San Diego, CA). Note the sharp edges of the holes, which transform the cannula into a rasp, augmenting the harvesting yield of this small-holed cannula.



Figure 2. A sterile canister with a 0.5-mm mesh cloth is used to rinse the fat with a sterile normal saline solution. The fat is then transferred to sterile syringes.

saline and transferred into 10-mL syringes. With the help of a double Luer-Lok adapter, the fat was brought into 1-mL syringes. A 23-gauge needle was mounted on the syringe for intradermal injection.

Injection technique. Before injection, the skin was marked with a fine pencil while the patient was standing and making exaggerated facial expressions. It was crucial that the skin be marked before application of the local anesthetic because the anesthetic solution can mask the fine wrinkles being treated. It is important to place the injections precisely in the wrinkle, as marked preoperatively.

A 23-gauge sharp needle was used for injection. The injection was made in a superficial dermal plane. The skin was pinched, with the wrinkle lying between the thumb and index finger (Figure 3). Linear thread injection of the fat was performed while the needle was withdrawn.

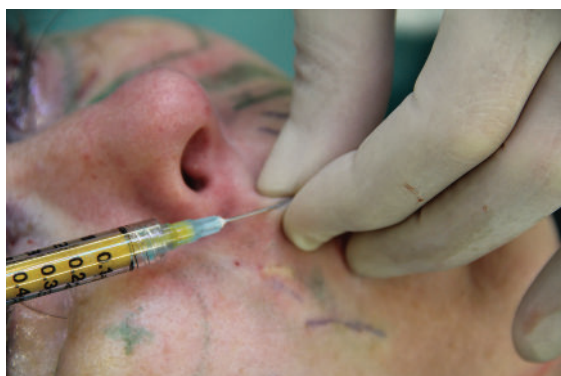

Figure 3. The skin is pinched with the wrinkle lying between the thumb and index finger. Linear thread injection of the fat is performed in the superficial dermal plane while the needle is withdrawn.

A video demonstrating the technique is available at www.aestheticsurgeryjournal.com. You may also use any smartphone to scan the code on the first page of this article to be taken directly to the video on www.YouTube.com.

Immediately after fat injection, the skin is blanched over the injected wrinkle. A slight overcorrection is advised because the blanching and overcorrection will normalize within a few hours, after resorption of the interstitial fluid. For deep wrinkles and folds separating the wrinkle from its deep attachments, subcision may be needed to achieve an optimal result. This can be achieved with a 17-gauge needle used as a “knife” under the skin. The 17-gauge needle is used only for subcision—not for intradermal injection. Intradermal fat injection can be performed as a supplementary and final procedure after classic lipofilling of deep folds (eg, nasolabial folds), with fine, blunt-tip cannulas. In some cases from this series, intradermal fat injection was combined with laser resurfacing in the same setting.

RESULTS

Of the 250 patients in this series, 222 were women (89%) and 28 were men (11%). The average patient age was 53 years (range, 35-71 years). A total of 282 treatments were performed in the 250 patients (average, 1.1 treatments per patient). In this series, the most common injection sites were the perioral and the glabellar regions. Thirty-two patients underwent a second intradermal fat grafting treatment, an average of 8 months after the first treatment. Refilling was performed in case of suboptimal outcome at the patient’s request or upon physician suggestion.

In 182 patients, the SNIF procedure was combined with a minimal-access cranial suspension (MACS) lift. In 68 cases, SNIF was performed as an isolated procedure. Among the isolated cases, 35 patients underwent fat grafting as a “maintenance procedure” for a previous MACS lift. For these patients, the SNIF procedure was performed

an average of 4.25 years after the MACS lift. For 31% ($n = 78$) of the 250 patients, an Erbium:YAG laser resurfacing procedure was performed in conjunction with the SNIF procedure.

The mean follow-up time was 14 months (range, 1 month to 3 years). Ninety-six patients have been followed for at least 1 year with stable results throughout that period; in this subgroup, no refilling was clinically necessary, nor was it requested by any of these patients. The results obtained with classic dermal fillers are known to last 3 to 6 months. Based on the data from this case series, the results of our SNIF technique are longer-lasting.

There were no indurations, cysts, or infections in this series, nor were there any serious complications such as necrosis or fat emboli due to intravascular injection. Bruising of the treated area occurred in 38% of patients ($n = 95$), and redness with some swelling occurred in 9% of patients ($n = 23$), all of which resolved an average of 4 days after the procedure. No surface irregularities, such as lumpiness or unevenness, were observed among our patients. No hypertrophy of the fat graft occurred due to weight gain. Although 1 patient lost a substantial amount of weight, her results remained stable.

Clinical results are shown in Figures 4-8.

DISCUSSION

Aging of the skin is a multifactorial process. Besides intrinsic and extrinsic factors, repetitive facial movements are a major mechanical factor contributing to wrinkle formation. Like a hinge always bending at the same place, muscle action in facial expression causes the appearance of lines on the surface of the skin. Initially, those lines are seen only during facial muscle contraction (dynamic wrinkles), but the repetitive nature of the movements causes the lines to become permanent over time (static wrinkles). Wrinkles can be treated by filling subdermal or intradermal planes. Filling in the subdermal plane is used to treat folds or deep wrinkles that result from underlying volume depletion. Conversely, fine wrinkles are treated with intradermal injections because they result from changes in the skin itself.

Since the earliest experiences with filler materials, physicians have been seeking the ideal filler. The ideal dermal filler must be nonteratogenic, noncarcinogenic, and biocompatible and must have the least possible number and severity of side effects. Availability and cost are also important criteria. The duration of the filler’s result must be taken into account.

Filler materials can be autologous or heterologous in origin. Autologous filler materials are those extracted from the patient’s own body (such as fat and dermal grafts). Heterologous fillers do not originate from the patient’s body but may be derived from normal substances found in the human body, such as collagen and hyaluronic acid. Collagen heterologous fillers are either xenogeneic (of animal origin) or allogeneic (of human origin). Other heterologous products are obtained from material that is

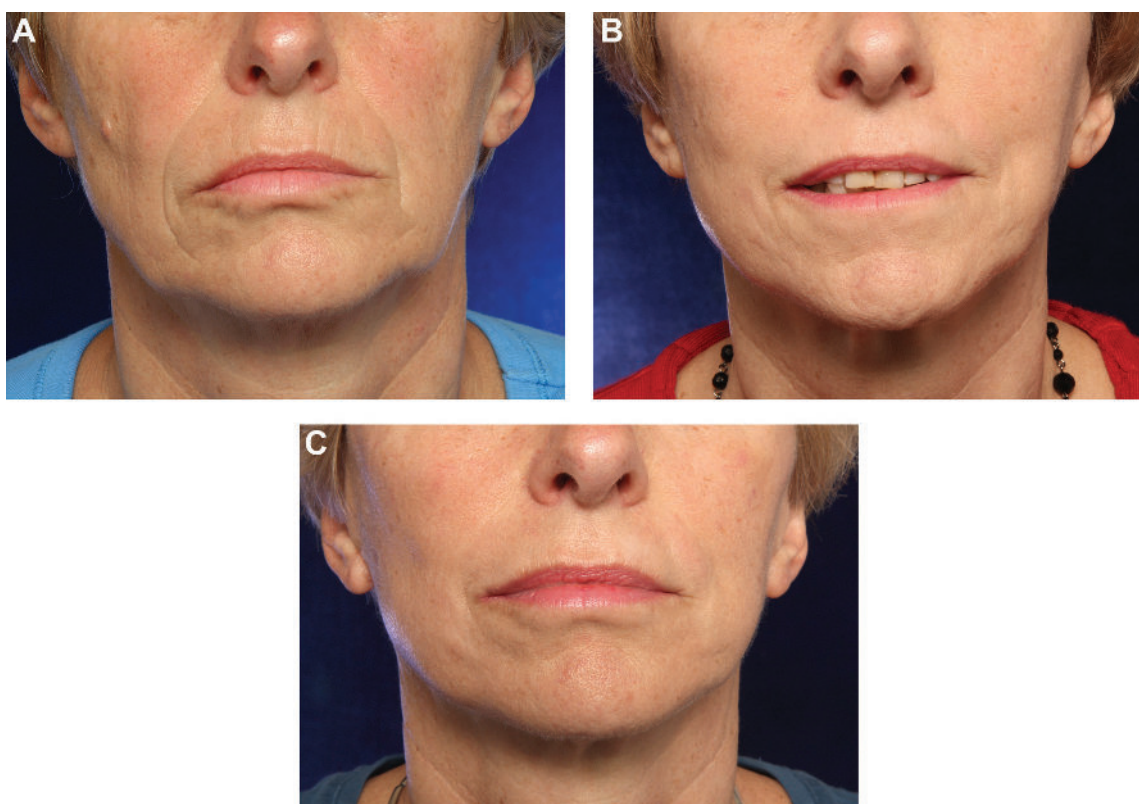


Figure 4. (A) This 66-year-old woman presented for facial rejuvenation, including perioral treatment. Note the fine wrinkles in her nasolabial crease and upper lip. (B) One year after MACS lift and SNIF treatment. The patient received 1.0 mL of fat per nasolabial crease and 0.5 mL spread over the wrinkles of the upper lip. Note the successful correction of her fine wrinkles. (C) Two years after treatment, the results are still visible.

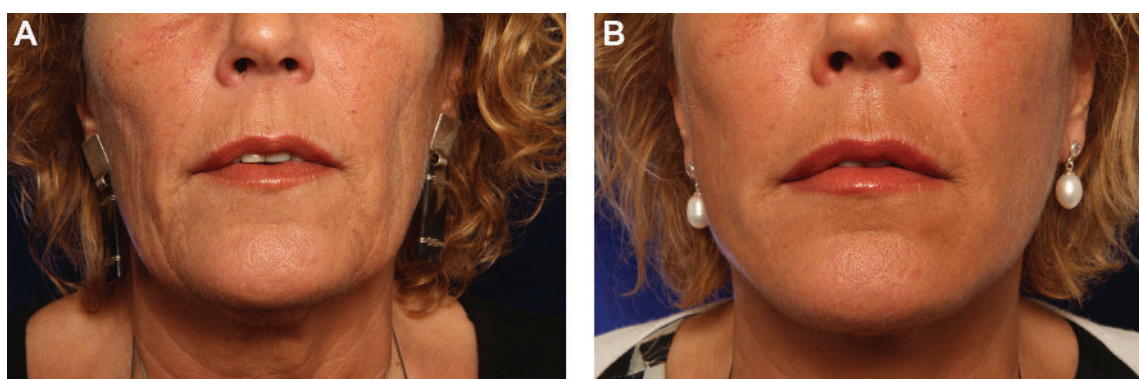


Figure 5. (A) This 56-year-old woman presented for facial rejuvenation. She desired improvement of the perioral area but refused laser resurfacing. (B) Six months after MACS lift and SNIF treatment. The patient received 0.7 mL of fat spread over the upper lip and 0.8 mL in each nasolabial and marionette crease. Note the improvement of the nasolabial crease and the “bar-code” aspect of the upper lip.

foreign to the human body (such as polylactic acid and polymethyl methacrylate) and are synthetically derived alloplastic products.⁸

In early experiences with heterologous dermal fillers, biocompatibility and allergy were a major concern, but current fillers are less allergenic (or nonallergenic).⁹

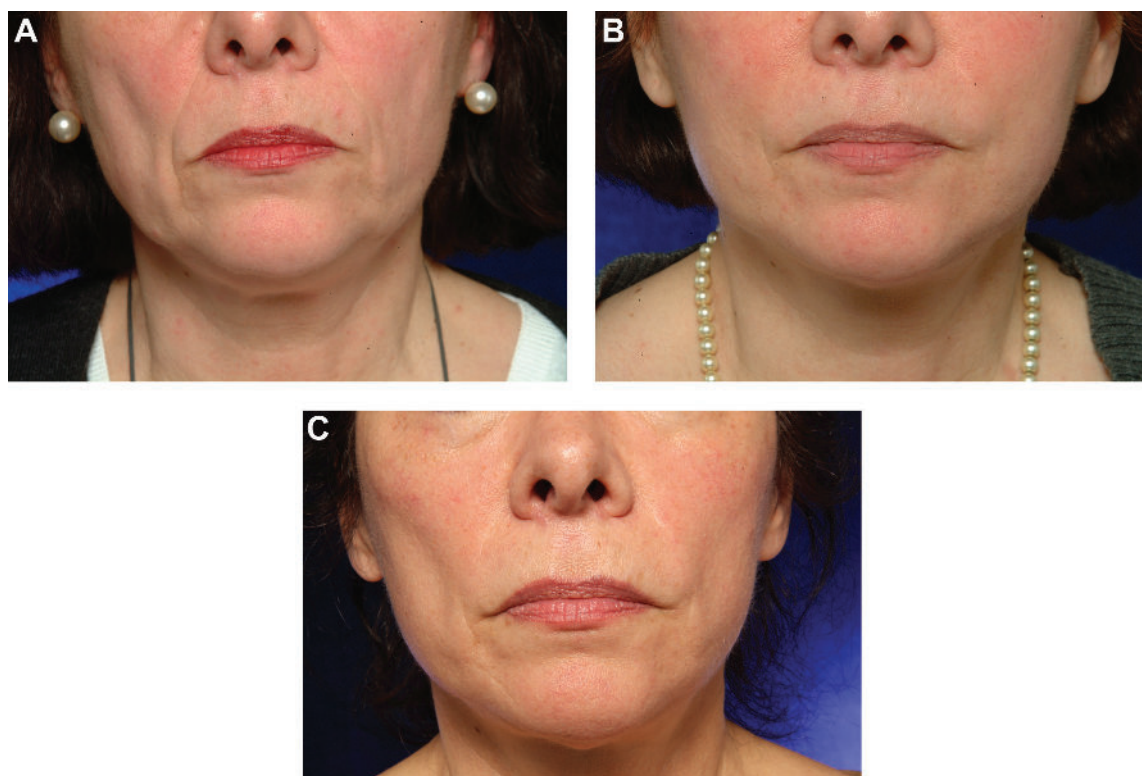


Figure 6. (A) This 58-year-old woman presented for facial rejuvenation. (B) One year after MACS lift and SNIF treatment. Note the improvement of the deep wrinkle at the nasolabial fold and the stability of the result. (C) Three years after treatment, the patient's results remained stable, even with 7 kg of weight loss.

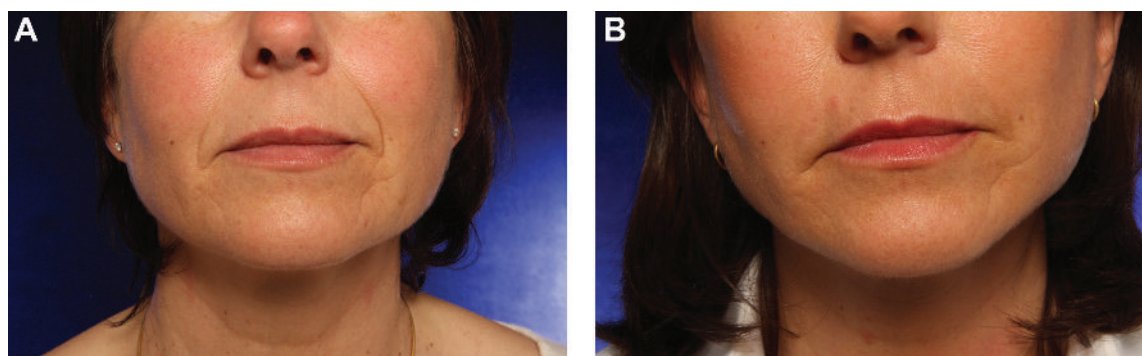


Figure 7. (A) This 52-year-old woman presented for facial rejuvenation. Note the bilateral deep creases in the nasolabial fold area. (B) One year after MACS lift and deep classical fat grafting of the nasolabial fold (1.5 mL), complemented by SNIF (0.5 mL in each crease, performed with a 23-gauge needle, and 1 mL in the white roll of the upper and lower lip, performed with a 21-gauge needle). Note the complete and stable eradication of the nasolabial crease and the accentuation of the white roll.

Bruising, redness, and swelling can occur around the injection site, but those effects resolve within a few days. Occasionally, delayed side effects may appear after several months, presenting as granulomas underneath the skin, which sometimes are permanent. These problems occur more frequently with permanent fillers and are more

difficult to treat. Other problems that can be encountered are chronic edema, lymphadenopathy, scarring, discoloration, and even skin ulceration.²

As stated previously, the availability and cost of the filler material are important considerations. An obvious advantage of pharmaceutical filler materials is their

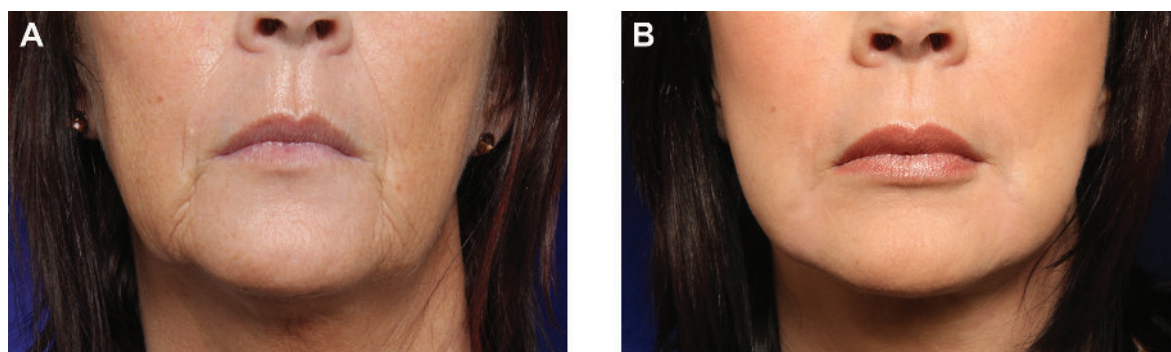


Figure 8. (A) This 58-year-old woman requested total facial rejuvenation. Note the deep perioral rhytids and grooves. (B) 1.5 years after MACS lift and SNIF treatment combined with Erbium:YAG laser resurfacing. A total of 11.8 mL of fat was injected in this patient. Deep classical blunt fat grafting: 1 mL per nasolabial fold, 2 mL per marionette groove. SNIF, 21-gauge: 2 mL in upper and lower vermilion border. SNIF, 23-gauge: 0.8 mL in each nasolabial crease, 0.5 mL spread over upper and lower lip rhytids, 1.4 mL and 1.3 mL in the right and left marionette rhytids (respectively). Laser resurfacing was performed with an Erbium:YAG laser, with 2 to 3 passes (1000 MJ) with a 5-mm spot. Notice the stable long-term correction of the rhytids obtained from the combination procedure. These results could not have been obtained with SNIF or laser resurfacing alone.




Figure 9. For a given volume, the radius of the fat particles is inversely proportional to its contact surface. Reducing the particle size increases the contact surface with the surrounding capillaries.

off-the-shelf use, but those products are expensive. In contrast, fat transfer to the deep layers of the face has been used in facial rejuvenation for years at a low cost. Fat transfer by injection was first reported in 1910, by Höllander, who used it to correct facial fat atrophy.¹⁰ The current techniques of fat injection have been popularized and described extensively by Coleman.¹¹ Besides partial resorption of the injected fat within the first 6 months, few complications and unfavorable results have occurred, and donor-site morbidity is low. The amount of fat required for intradermal injection is very small (ranging from 0.5 to 5 mL). If intradermal fat transfer is performed without deep lipofilling, fat harvesting is not time-consuming (only 2.5–25 mL of lipoaspirate will be needed) and locating an appropriate donor site is seldom a problem even in lean patients.

Based on the experiences of previous authors, coupled with modifications and refinements of previously described techniques, we developed the SNIF technique, the intent of which is to obtain particles of fat that are as small as possible. We use harvesting cannulas of 2 to 3 mm in diameter, which contain multiple small-diameter (1-mm) sharp holes. A yield of 1 mL of fat per 5 mL of aspirate can be expected, which is relatively low compared with that obtained by classical harvesting cannulas and is achievable because of the multiple, fine, sharp holes of the cannula.

The fat is then filtered through a sterilized nylon cloth with a mesh size of 0.5 mm. We began using this technique before the availability of “closed” systems, and given the favorable results and low cost, we have continued to use it. The filtered fat can then be injected easily through a 23-gauge needle. The 23-gauge size was necessary because the prepared fat could not be injected through needles of smaller diameter without encountering frequent blockage.

The key to successful fat grafting is the use of micrografts.¹² The radius of the fat particle is inversely proportional to its contact surface. This means that for the same volume of injected fat, reducing the diameter by half will double the contact surface (Figure 9). A larger contact surface means better contact with the capillaries in the recipient area and thus a better graft survival rate with less need for overcorrection, which translates into lower morbidity. We overcorrected the wrinkles slightly (as described) because some of the injected interstitial fluid undergoes resorption within 1.5 hours of injection. With respect to long-term results, the degree of correction observed 1.5 hours postinjection is what has remained since then. The slight overcorrection was not maintained in any patient. None of our patients has gained a substantial amount of

weight since the procedure; however, we observed stable results in a patient who has lost weight (Figure 6).

A major concern with sharp injection of soft tissue fillers in the face is the rare occurrence of intravascular injection, with embolization of certain vascular territories. This can lead to skin necrosis at the injection site¹³⁻¹⁵ and to even more catastrophic problems such as blindness or cerebral stroke.¹⁶⁻¹⁸ When treating the face, we always prepare the surgical area with injection of a local anesthetic solution that contains adrenaline, regardless of whether the patient is scheduled to receive local or general anesthesia (lidocaine 0.3%, adrenaline 1/650 000). This is important because the vasoconstriction caused by adrenaline minimizes the risk of intravascular injection and, to some degree, the bruising. Injection is always performed in a very superficial dermal plane while the needle is being withdrawn, again to minimize the risk of intravascular invasion. Also, squeezing of the skin (with the wrinkle between index finger and thumb) during fat injection will occlude any possible vessel in the direct vicinity. The classical (deep) subdermal fat transfer is always performed with blunt cannulas, as described previously.¹⁹

In our patients who underwent intradermal fat injections with subsequent laser resurfacing (Erbium:YAG), superficial resurfacing usually was sufficient because wrinkle filling had already been achieved. Thus, the down-time associated with laser resurfacing was reduced, as was the possibility of complications such as hypopigmentation. When laser resurfacing is combined with intradermal fat injections, the effects are synergistic. This observation is contrary to findings that laser resurfacing of skin recently treated with a heterologous dermal filler may cause degradation or liquefaction of the underlying filler material.²⁰ Intradermal fat injections are also a viable alternative for patients who seek skin rejuvenation but refuse laser resurfacing.

Another advantage of fat injection is its use of autologous material that does not biodegrade with time; thus, its effect is more permanent. In addition, fat injection is not associated with the problems common to nonautologous permanent fillers. Very few problems (redness, swelling, and bruising), all minimal, were encountered with our SNIF procedure. Bruising was the most common adverse effect (38% of patients). No major problems have been encountered.

Possible problems that may occur with classical (deep subcutaneous) fat grafting include palpable nodules, firmness, fat necrosis, and fat cysts. None of these complications were observed in our patient population, probably because only small amounts of small-diameter fat particles were used, and these were injected into well-vascularized tissue. Overcorrection and blanching of the skin over the wrinkle, which are common with intradermal fat injections, resolve after approximately 1 hour due to resorption of the suspension solution.

A limitation of the present study is that the results are not quantifiable; they are compared only with our own clinical experience with synthetic resorbable fillers.

However, we are currently preparing larger retrospective and prospective studies that compare SNIF and synthetic fillers. To our knowledge, use of a sharp-needle procedure for intradermal fat injection has not been described previously in the literature. This technique is proposed as a valuable supplement to the current list of dermal filling procedures.

CONCLUSIONS

The SNIF technique is a safe, effective, and inexpensive alternative to procedures that use synthetic filler materials, and the results are longer lasting. Contrary to popular belief, intradermal fat grafting can be performed safely with a sharp needle, so long as it is done in a superficial dermal plane while the needle is being withdrawn. The harvesting and injection techniques should be performed with precision in order to achieve optimal results and avoid complications.

Disclosures

The authors declared no potential conflicts of interest with respect to the research, authorship, and publication of this article.

Funding

The authors received no financial support for the research, authorship, and publication of this article.

REFERENCES

1. Farage MA, Miller KW, Elsner P, Maibach HI. Intrinsic and extrinsic factors in skin aging: a review. *Int J Cosmet Sci* 2008;30:87-95.
2. De Boulle K. Management of complications after implantation of fillers. *J Cosmet Dermatol* 2004;3:2-15.
3. Cohen JL. Understanding, avoiding, and managing dermal filler complications. *Dermatol Surg* 2008;34(suppl 1):S92-S99.
4. Gold M. The science and art of hyaluronic acid dermal filler use in esthetic applications. *J Cosmet Dermatol* 2009;8:301-307.
5. Price RD, Berry MG, Navsaria HA. Hyaluronic acid: the scientific and clinical evidence. *J Plast Reconstr Aesthet Surg* 2007;60:1110-1119.
6. Baumann L. Replacing dermal constituents lost through aging with dermal fillers. *Semin Cutan Med Surg* 2004;23:160-166.
7. Klein JA. Anesthesia for liposuction in dermatologic surgery. *J Dermatol Surg Oncol* 1988;14:1124-1132.
8. Eppley BL, Babak D. Injectable soft-tissue fillers: clinical overview. *Plast Reconstr Surg* 2006;118:98e-106e.
9. Duffy DM. Complications of fillers: overview. *Dermatol Surg* 2005;31(11 pt 2):1626-1633.
10. Höllander E. Über einen Fall von progressiver Fettatrophie und seinen kosmetischen Ersatz durch humans Fett (About a case of progressive fat atrophy and its cosmetic

- replacement by human fat). *Münch Medizin Wochenschr* 1910;34:1794-1795.
11. Coleman SR. *Structural Fat Grafting*. St Louis, MO: Quality Medical Publishing; 2004.
 12. Tonnard PL, Verpaele AM. Combined fat grafting with MACS-lift face lift and with facial reshaping procedures. In: Coleman SR, Mazzola RF, editors. *Fat Injection From Filling to Rejuvenation*. St Louis, MO: Quality Medical Publishing; 2009.
 13. Glaich AS, Cohen JL, Goldberg LH. Injection necrosis of the glabella: protocol for prevention and treatment after use of dermal fillers. *Dermatol Surg* 2006;32:276-281.
 14. Inoue K, Sato K, Matsumoto D, Gonda K, Yoshimura K. Arterial embolization and skin necrosis of the nasal ala following injection of dermal fillers. *Plast Reconstr Surg* 2008;121:127e-128e.
 15. Georgescu D, Jones Y, McCann JD, Anderson RL. Skin necrosis after calcium hydroxylapatite injection into the glabellar and nasolabial folds. *Ophthalm Plast Reconstr Surg* 2009;25:498-499.
 16. Peter S, Mennel S. Retinal branch artery occlusion following injection of hyaluronic acid (Restylane). *Clin Exp Ophthalmol* 2006;34:363-364.
 17. Hexsel DM, Hexsel CL, Iyengar V. Liquid injectable silicone: history, mechanism of action, indications, technique, and complications. *Semin Cutan Med Surg* 2003;22:107-114.
 18. Sung MS, Kim HG, Woo KI, Kim YD. Ocular ischemia and ischemic oculomotor nerve palsy after vascular embolization of injectable calcium hydroxylapatite filler. *Ophthalm Plast Reconstr Surg* 2010;26:289-291.
 19. Coleman SR. Avoidance of arterial occlusion from injection of soft tissue fillers. *Aesthet Surg J* 2002;22:555-557.
 20. Alam M, Levy R, Pavjani U, et al. Safety of radiofrequency treatment over human skin previously injected with medium-term injectable soft-tissue augmentation materials: a controlled pilot trial. *Lasers Surg Med* 2006;38:205.